



PATIENT

Leila Daudon

SPECIES

Canine

BREED

Mix

SEX

FS

AGE

7 years

WEIGHT

22.8lbs

PRESENTING CLINICAL SIGNS

History: Abdominal distension and heart murmur. It was noticed in Feb 2022 when pt did not want to defecate.

Abnormal PE/Chem/CBC/UA Results: PE: abdominal distension with fluid wave Grade 4/6 systolic HM on both sides. BW: CBC: Hematocrit 30.4 37.3 - 61.7 %, Hemoglobin 10.3 13.1 - 20.5 g/dL WBC 25.58 5.05 - 16.76 K/ μ L, Neutrophils 15.88 2.95 - 11.64 K/ μ L, Eosinophils 3.64 0.06 - 1.23 K/ μ L, Monocytes 2.12 0.16 - 1.12 K/ μ L CHEM: Glucose 67 74 - 143 mg/dL rest of chem is wnl 4DX: only positive to Heartworm in Jan 2022 Direct positive on Feb 2022

ECHOCARDIOGRAM FINDINGS

2D, m-mode, color flow and doppler imaging is available. Mild diffuse thickening of mitral valve with no prolapse into the left atrial lumen. Mild mitral regurgitation, normal left atrial dimension. Normal LV diameter with adequate function. Subtle septal flattening in systole. The TV appears mildly thickened with severe tricuspid regurgitation. Velocity consistent with mild pulmonary hypertension. Severe right atrial and ventricular dilation with evidence of mild hypertrophy. The MPA and branches are mildly dilated. The pulmonic and aortic valves are normal in morphology and mobility. Normal pulmonic and aortic outflow velocities with laminar flow. Concern for adult worm in the RA; difficult to confirm. No worms seen in the distal pulmonary artery or branches. Mild pulmonic insufficiency. No aortic insufficiency. Scant pericardial effusion. No pleural effusion noted. Large volume ascites with hepatic congestion.

CARDIAC CHART

INTERPRETED BY

Maggie Machen Lamy,
DVM, DACVIM
(Cardiology)

IMAGING PERFORMED BY

G. Ferrer, DVM

HOSPITAL NAME

Paseos Veterinary
Center

REFERRING VET

Dr. Cruz

INVOICE

24146

DATE

5/11/22

CANINE CARDIAC PARAMETERS	MR VMAX (m/s)	TR VMAX (m/s)	LA/AO (Boon method)	LA/AO (Heart Base; Swe)	FS (%)	EF (%)	EPSS (cm)
NORMAL PARAMETER	4.5-5.5	<2.7	1.3	<1.6	28-40	40-100	<0.6
PATIENT	5.5	3.0	NM	1.2	42	80	0.12
CANINE CARDIAC PARAMETERS	HR (BPM)	AV VMAX (m/s)	PV MAX (m/s)	BODY WEIGHT (kg)	LA 2D short axis Base view (cm)	LVIDd Avg; 2D and m-mode short axis (cm)	LVIDs Avg; 2D and m-mode short axis (cm)
NORMAL PARAMETER	50-100	0.7-1.7	0.7-1.6	BELOW	BELOW	BELOW	BELOW
PATIENT	190	0.6	1.1	10	1.7	2.4	1.4
*Normal chamber parameters expressed as a mean value (SD)				3	1.27 (5.3)	2.46 (2.46)	1.36 (5.5)
BODY WEIGHT DEPENDENT PARAMETERS				5	1.40 (4.5)	2.74 (5.2)	1.60 (4.7)
*Note: All measurements based upon multi-modal images and methods. An average value is reported.				10	1.50 (3.8)	3.27 (3.5)	2.06 (3.1)
				15	1.83 (2.0)	3.71 (2.4)	2.43 (2.1)
				20	2.02 (1.9)	4.14 (2.2)	2.80 (2.0)
				25	2.18 (2.4)	4.48 (2.9)	3.10 (2.5)
				30	2.33 (3.3)	4.83 (3.9)	3.39 (3.4)
				35	2.48 (4.3)	5.17 (5.0)	3.69 (4.5)
				40	2.62 (5.2)	5.48 (6.1)	3.96 (5.4)
				50	2.88 (7.1)	6.07 (8.3)	4.46 (7.4)

Adapted from June Boon, Veterinary Echocardiography, 1998
Rishniw M and Hollis NE, J Vet Intern Med 2000; 14:429-435
Hansson et al, Vet Rad and Ultrasound 2002
Bonagura et al. Echocardiography: principles of interpretation, Vet Clin North Am 15:1177, 1995



PATIENT

Leila Daudon

SPECIES

Canine

BREED

Mix

SEX

FS

AGE

7 years

WEIGHT

22.8lbs

INTERPRETED BY

Maggie Machen Lamy,
DVM, DACVIM
(Cardiology)

IMAGING PERFORMED BY

G. Ferrer, DVM

HOSPITAL NAME

Paseos Veterinary
Center

REFERRING VET

Dr. Cruz

INVOICE

24146

DATE

5/11/22

INTERPRETATION OF THE FINDINGS & FURTHER RECOMMENDATIONS

Suspicion for an adult heartworm infestation, leading to severe dilation of the right heart and pulmonary artery. The visualization is highly suspicious (see below), although difficult to confirm and albeit in an atypical location. Association with the TV annulus is also a possibility. It is important to note that even with good visualization ultrasound is not entirely sensitive (i.e., adult worms may easily be missed either peripherally or elsewhere). Additionally the TR velocity is only mildly elevated which is unexpected. Regardless, there is concern for significant pulmonary hypertension in this study (TR velocity thought to be an under-estimation), as evidenced by secondary RA/RV changes and severe TR. This is certainly a concern going forward and reassessing in the future is recommended to determine progression. Even if we are able to safely clear the infestation, these cardiac changes may be irreversible, and the prognosis is guarded to poor long term. There is also mild MR without left heart enlargement, which is relatively insignificant at this time.

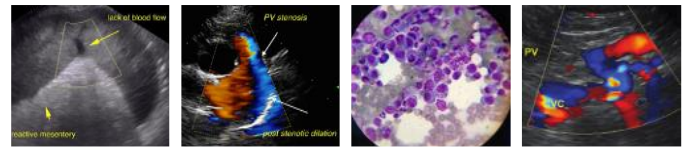
Heartworms can cause significant damage to the lung tissue leading to pulmonary damage, pulmonary hypertension and clinical signs such as coughing, decreased ability to exercise, or difficulty breathing. Disease severity can range from an asymptomatic dog with few worms to dogs with severe respiratory signs. In the most severe cases, caval syndrome may develop due to a very high worm burden sheering blood cells as they pass through the heart. Caval syndrome is a life-threatening emergency that requires immediate surgical removal of the worms.

Unfortunately, the degree of right-sided damage has led to **congestive heart failure as evidenced by large volume ascites**. Given the somewhat atypical findings, a primary right heart issue leading to CHF is also a possibility and difficult to sort at this time. A therapeutic abdominocentesis is recommended to improve comfort. Additionally, immediate medical stabilization is recommended including diuretics, Sildenafil, Pimobendan and treatment for the cough (hydrocodone, Doxycycline). If extraction would be a possibility from a financial standpoint, I would **consider immediate referral to a local cardiologist** for advanced echocardiography and evaluation. If that is not a possibility, utilizing the standard approach to heartworm treatment as dictated by the American Heartworm Society is recommended, including 30 days of doxycycline and heart guard prior to continuing the split Immiticide protocol. Please see website and protocol for specific information.

There is high risk for thromboembolism in any patient, however those with adult worms in the PA are no question at elevated risk. At this time, exercise restriction is paramount, including cage rest with leash_walks only, as a worm embolus can be a life-threatening complication of the disease. This should be continued for an additional 6-8 weeks following therapy.

Modifications to this protocol are sometimes elected depending on individual circumstances which may involve fewer injections or a "slow kill" method. These are not, however, our standard recommendation as alternate treatment may not result in effective treatment of the infestation.

Following treatment, retest for heartworm disease 6 months after completing the full course of therapy. Anesthesia is NOT advised prior to completing the protocol, as vasodilation can lead to increased risk for an embolus. Prognosis is guarded, as the right heart/MPA changes are often permanent and may cause clinical signs (exertional syncope/dyspnea, right-sided CHF) in the future. It must be reiterated that this patient is considered end-stage, and our goals are to improve QOL for the short term. If QOL suffers, humane euthanasia should be considered.



PATIENT

Leila Daudon

SPECIES

Canine

BREED

Mix

SEX

FS

AGE

7 years

WEIGHT

22.8lbs

INTERPRETED BY

Maggie Machen Lamy,
DVM, DACVIM
(Cardiology)

IMAGING PERFORMED BY

G. Ferrer, DVM

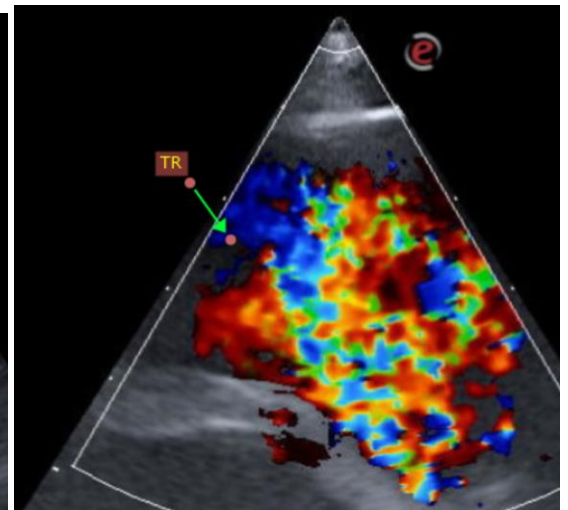
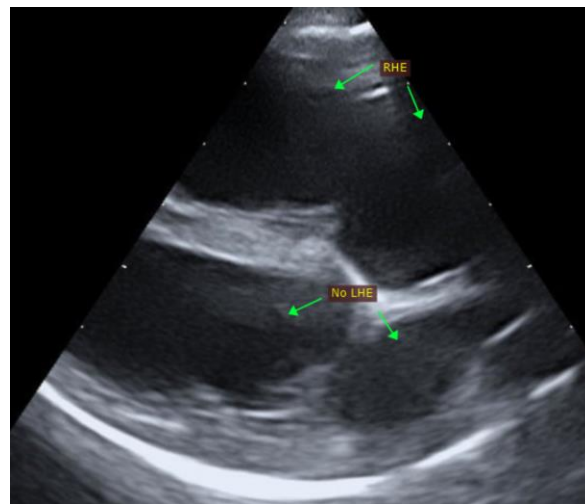
During therapy, there is high risk for a worm embolus and breathing rate and effort should be monitored closely. Anti-inflammatory prednisone can be used if becomes symptomatic. Patient will be at high risk for developing clinical signs due to pulmonary hypertension with age given the inherent secondary inflammation and damage to the pulmonary vasculature and lungs, and periodic rechecks may be helpful. Monitor for exertional dyspnea or fainting episodes going forward.

PLAN

Abdominocentesis if needed, immediate referral as discussed. Institute Lasix 1-2mg/kg PO q12h. Institute Spironolactone 1-2mg/kg PO q12h. Institute Pimobendan 0.3mg/kg PO q12h. Institute Sildenafil 1-2mg/kg PO q8h. Institute Doxycycline/Heartguard as dictated by the HW society. If patient's ascites persists/worsens, a course of anti-inflammatory prednisone is recommended. Baseline ECG strongly recommended due to tachycardia.

Once heartworm negative, a recheck echocardiogram and chest radiographs are recommended in 6 months to reassess right heart changes.

IMAGES



HOSPITAL NAME

Paseos Veterinary
Center

REFERRING VET

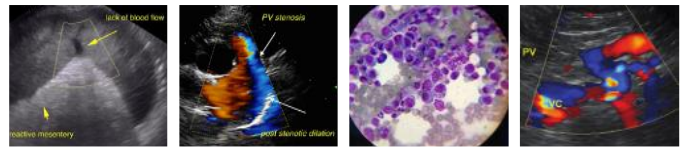
Dr. Cruz

INVOICE

24146

DATE

5/11/22



PATIENT

Leila Daudon

SPECIES

Canine

BREED

Mix

SEX

FS

AGE

7 years

WEIGHT

22.8lbs

INTERPRETED BY

Maggie Machen Lamy,
DVM, DACVIM
(Cardiology)

**IMAGING
PERFORMED BY**

G. Ferrer, DVM

HOSPITAL NAME

Paseos Veterinary
Center

REFERRING VET

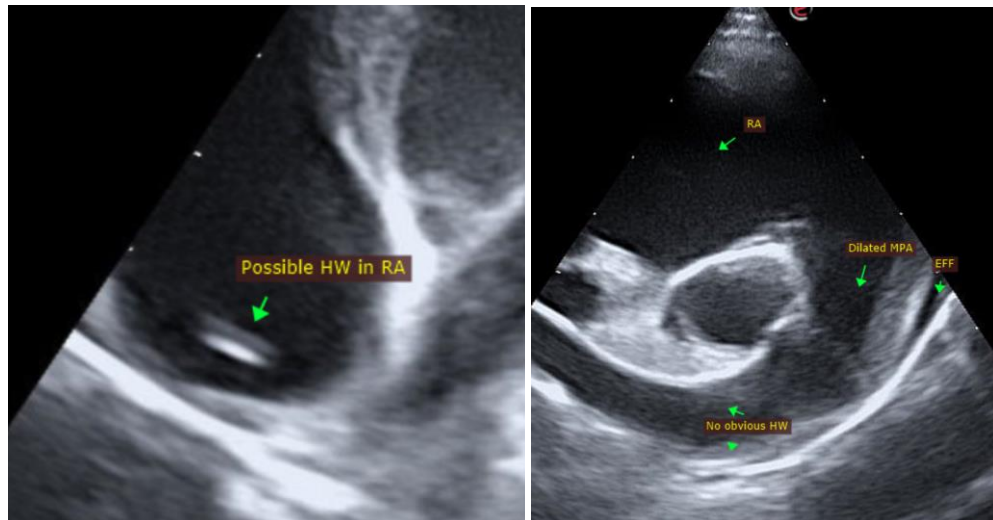
Dr. Cruz

INVOICE

24146

DATE

5/11/22



The information and recommendations provided are based on the images presented by the referring veterinarian. No evaluation can be communicated regarding pathology that was not visible in the image/video clips provided.

Thank you for this referral. If the clinical or image interpretation does not parallel your findings or if I can be of any further assistance, please contact me.

Maggie Machen Lamy, DVM
Diplomate of the American College of Veterinary Internal Medicine (Cardiology)
info@sonopath.com